

The Use of Phosphatidylcholine for Correction of Localized Fat Deposits

Patrícia Guedes Rittes, M.D.

São Paulo, Brazil

Abstract. Subjects with localized fat deposits commonly receive suction lipectomy as a cosmetic procedure. A new office procedure for correction of those superficial fat deposits was applied in 50 patients by injection of phosphatidylcholine. The method itself consists of using a 3OG1/2 insulin needle to inject about 5 ml (250 mg/5 ml) of phosphatidylcholine into the fat, distributing it evenly in an 80-cm² area. Pre- and posttreatment photographs were taken for technical planning and analysis of the results over the long term. A clear improvement occurred in all, with a marked reduction of the fat deposits without recurrence over a 2-year follow-up period and no weight gain. The injection of phosphatidylcholine into the fat deposits is a simple office procedure that can sometimes postpone or even replace surgery and liposuction.

Key words: Lipostabil—Phosphatidylcholine—Fat deposits

Introduction

A new and simple technique for treating fat deposits is described in this article. Liposuction is one of the most commonly performed cosmetic procedures [1] for the treatment of minimal to moderate localized fat deposits. The safety of the procedure has been addressed regarding patient selection, complications, and results.

I have been using this technique since 1995, achieving very good results. At first, only fat pads [2] were the focus of this procedure, which was introduced to the scientific community at the Dermatologic Brazilian Congress in 1999 and published by

Dermatologic Surgery in April 2001. Three years later, localized fat is the goal to be achieved, and due to the excellent results, with no complications or adverse effects, this procedure has proved to be extremely efficient in contouring and remodeling superficial fat areas, such as arms, abdomen, thigh, and neck. Treating these deformities by surgical resection as well as liposuction presents some adverse effects and surgical risks.

Pre- and postprocedure photographs of the cases studied document the new method described. Patient satisfaction and absence of recurrence were the best evaluators of the results. The intervals are discussed further under Materials and Methods. The procedure is simple and can be done in the office.

Various studies have reported the use of phosphatidylcholine (Lipostabil) for reduction of systemic levels of cholesterol and triglycerides [3,4]. However, a study by Bobkova et al. [5] verified that upon increasing phosphatidylcholine, the cell membranes improved their receptor properties, augmented their sensitivity to insulin, and accelerated lipolysis. Hence there is a marked reduction in atheromatous plaques and the level of aortic cholesterol, without a reduction in plasma cholesterol. In other studies Lipostabil was employed intravenously in patients with cardiac ischemia [6].

Phosphatidylcholine is a bile component and is responsible for lipid emulsification from diet [7].

Materials and Methods

Preoperative Analysis

Preoperatively, it is essential to discuss the patient's real expectations. Evaluation of the size and location of the fat deposits is necessary.

The method itself consists of using a 3OG1/2 insulin needle to inject about 5 ml (250 mg/5 ml) of phosphatidylcholine into the fat, distributing it

Correspondence to Patrícia Guedes Rittes, M.D., Rua Afonso Brás 864, cj. 72, Vila Nova Conceição, São Paulo, SP, Brazil CEP 04511-011; email: prittes@terra.com.br

evenly in an 80-cm² area. The procedure is initiated with the patient seated or lying down, depending on the site to be injected. The solution is injected into the fat deposit localized in the abdomen, neck, arms, or thighs (the portion of the leg between the hip and the knee), based on individual needs. Local anesthetics are unnecessary. Immediately after application, infiltrative edema occurs, with local erythema and a mild burning sensation, usually lasting 15 min.

Swelling and redness at injection sites occur during the next 6 h and last about 72 h. Nodule formation and hematoma can occur and may take 15 to 30 days to resolve. Fifty patients, all with fat deposits, varying in volume, were studied: 40 women and 10 men, with ages ranging from 25 to 60 years. Injections were applied at intervals of 15 days as follows:

35 cases with four treatments (70%),
10 cases with two treatments (20%), and
5 cases with one treatment (10%).

This time interval was necessary for the edema caused by injection to completely disappear. The number of additional injections was determined by the fat volume.

This technique is indicated for all patients with fat deposits not due to obesity, especially for those patients for whom liposuction or a surgical procedure cannot be performed due to surgical risks. The number of treatments was dependent on physician and patient satisfaction. According to the results obtained, due to the appearance of the remaining fat deposits, the physician decided on the need for further injections.

When selecting patients, those of ideal weight (not obese) and presenting only localized fat were chosen. In some specific cases the patient presented some fat excess only in the area above the waist and the ideal weight from the waist down (e.g., patients under chronic cortical steroid therapy). Only patients over 25 years old were accepted, as till this age the organic metabolism works at 100% of its capacity.

The solution is evenly distributed. Observing and mentally calculating, the area to be treated is divided in to six parts, and then approx. 0.8 ml is injected in each part, distributing the (0.2 ml) remaining substance in areas identified to need more. It is understood that the substance remains in the treated area, because right after the injection, localized swelling and some erythema occur for about 48 h, not invading any other distant site.

Tape measurements, were not taken due to the difficulty in using a tape measure, which is not precise, because if it is not always placed with the same accuracy (above or below the previous tape measurement), the first mark may suffer some alteration. Also, in the premenstrual period the woman's body measurements may change due to water retention, without significance. That is why photographs were taken, to give a more accurate visualization of the before and after status.

Informed consent was obtained from all individuals, and this study conformed to the guidelines of the 1975 Declaration of Helsinki.

Contraindications

- Obesity: This procedure is indicated only for small fat deposit: it is not a slimming treatment.
- Age under 25 years old (explained above)
- Pregnancy

The use of phosphatidylcholine should be restricted to small localized fat deposits, with the same indication as for liposuction, an alternative for patients. It is not indicated for obese patients, as it is not a slimming treatment, with some exceptions such as the alterations of the body contour or obesity caused by chronic use of systemic corticosteroid therapy.

Evaluation of each case is extremely important for and when deciding to use this technique: patients must be aware of the reasonably expected results and overexpectations must not be created.

Complications

No complications were observed beyond the symptoms described above, that is, bruises, edema, and erythema that lasted from 48 to 72 h and the appearance of postinflammatory nodules which disappear within 30 days at the most. No atrophy occurred.

Long-Term Follow-Up

Long-term follow-up has reached 4 years, with no return of local fat as long as there is no weight gain (over 4 kg).

Results

Cosmetic improvement occurred in all patients with fat deposits. The amount of fat reduction was not tape-measured but photographs show the results (see Figs. 1 and 2). Patients have not shown a return of the local fat for approximately 4 years, but the treatment can be repeated if necessary. When there is a fat increase, despite gaining or not gaining weight, the procedure can be repeated. In the cases mentioned in the protocol, no repeat treatment was performed. At this time more than 500 patients have been treated.

Discussion

The patient should be informed that this method treats only the localized fat deposit, which is a different entity from obesity and lax skin. The objective of this study is to improve corporal contour by re-

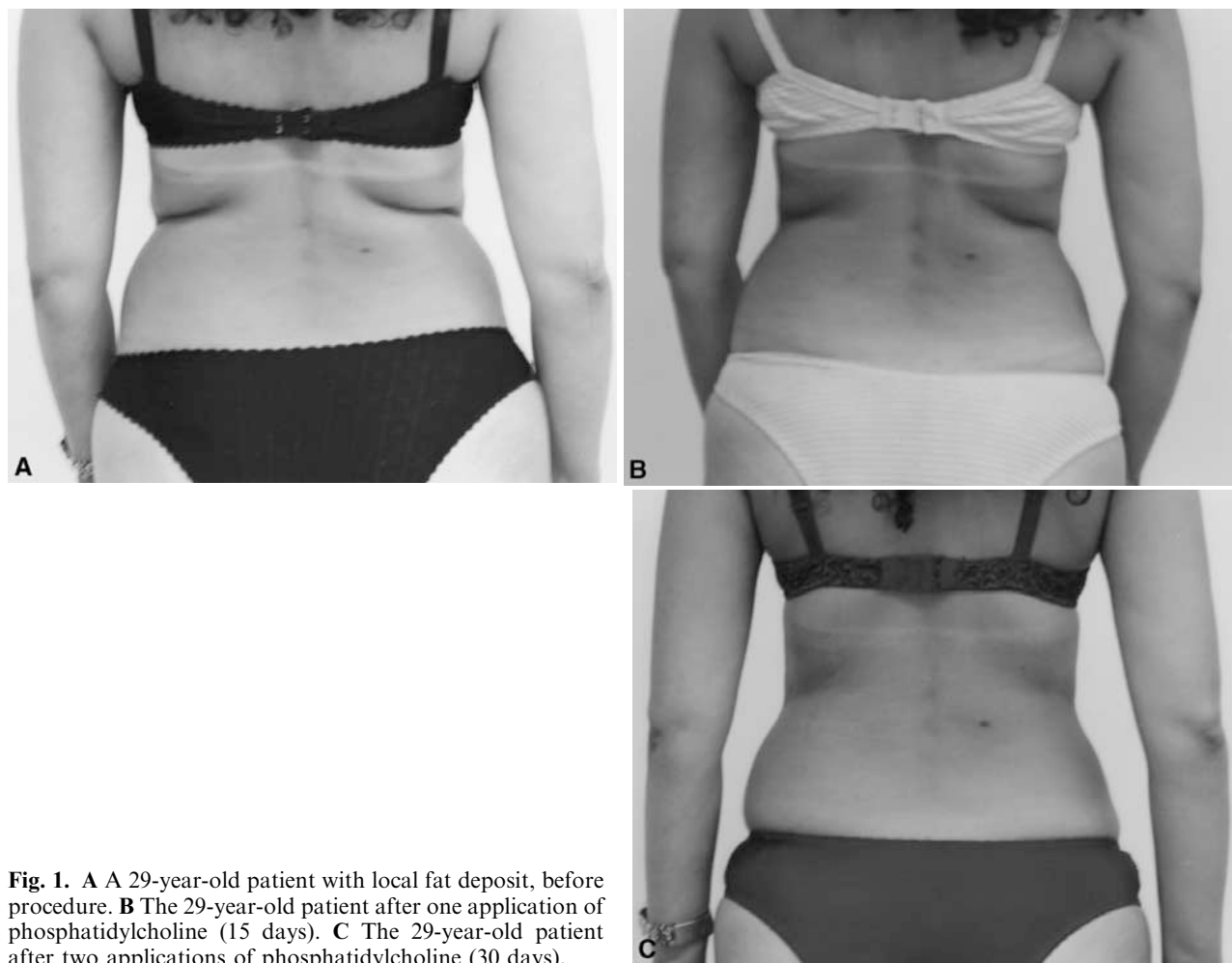


Fig. 1. **A** A 29-year-old patient with local fat deposit, before procedure. **B** The 29-year-old patient after one application of phosphatidylcholine (15 days). **C** The 29-year-old patient after two applications of phosphatidylcholine (30 days).

ducing fat deposits. Our intention was to obtain better cosmetic results in those patients unsuitable for, or having no interest in, surgery. The final results are similar to those of both liposuction and surgery. Up to now, the only treatment has been liposuction and/or surgery, and this study provides a simple, rapid, office procedure without surgical risks. The cosmetic results are satisfactory from both the patients' and the dermatologist's point of view.

Patients were followed for 4 years with no return of the local fat, as long as there was no weight gain over 4 kg. Not a single case of atrophy or complication was observed in more than 500 patients.

Serology

Serologic study was not done in these cases, but the effects of Lipostabil-Forte containing unsaturated fatty acids on serum lipid concentrations, plasma and erythrocyte lipid and phospholipid fractions, and immunoreactive insulin and thyroidal hormone levels were studied in 30 patients with coronary heart dis-

ease. During the therapy of all patients, within 1 month and, occasionally, at 3 and 6 months, there was a statistically significant reduction in serum triglycerides, an increase in relative erythrocyte phospholipid levels and in plasma and erythrocyte phosphatidylcholine, and a reversal of hyperinsulinemia and improvement of thyroid function [5].

Also the maximum nontoxic intravenous (iv) dose of lecithin (purified soya phospholipids containing 75 to 80% phosphatidylcholine) for the mouse, rat, and rabbit was 4, 2, and 0.5 g/kg, respectively [8]. The maximal nontoxic subcutaneous dose for the mouse, rat, and rabbit was 10, 4, and 1 g/kg, respectively [9].

Conclusions

- This procedure does not reduce skin laxity.
- There is a natural postoperative appearance without a surgical "look."
- Surgical or anesthetic risks are eliminated. It is suitable for patients with intense fear of hospitalization.
- It is a rapid office procedure, eliminating the need for hospitalization.

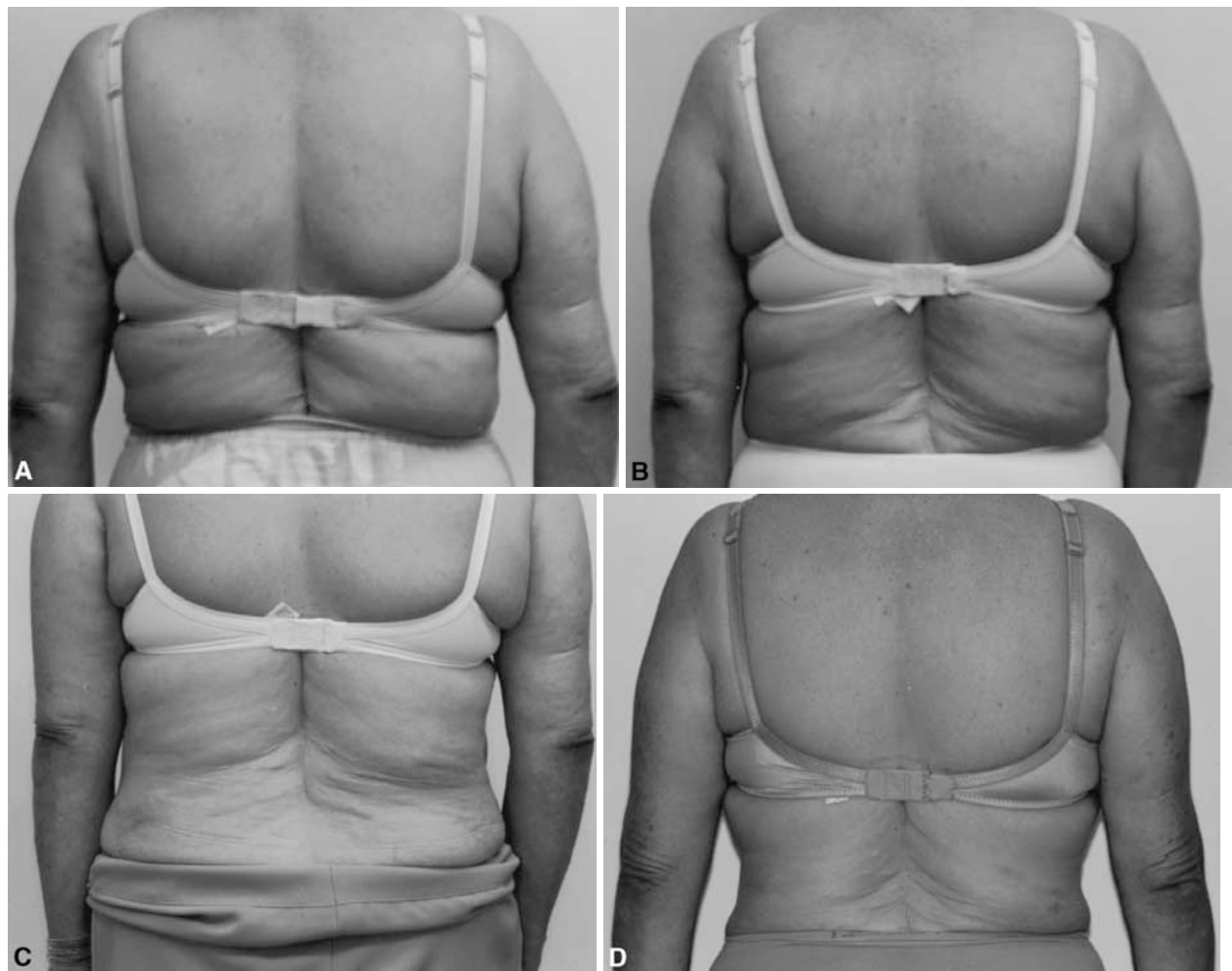

Fig. 2. **A** A 57-year-old patient with local fat deposit due to chronic cortisone use, before procedure. **B.** The 57-year-old patient after two applications of phosphatidylcholine (30 days). **C.** The 57-year-old patient after four applications of phosphatidylcholine (60 days). **D.** The 57-year-old patient after eight applications of phosphatidylcholine (120 days).

- Patient satisfaction is good, there are no skin scars or irregularities, and the cosmetic results are good.
- There is less postoperative discomfort than with surgery.

The technique presented has been performed for the past 4 years without any complications. Recurrence or skin laxity was not noted after treatment.

Hopefully, this technique will be of additional help to physicians and surgeons in the clinical approach to these deformities that are sometimes so vexing to patients.

References

1. Markey AC: Liposuction in cosmetic dermatology. *Clin Exp Dermatol* **26**:3, 2001
2. Rittes P: The use of phosphatidylcholine for correction of lower lid bulging due to prominent fat pads. *Dermatol Surg* **27**:391, 2001
3. Warembourg H, Jaillard: Experimentation clinique du lipostabil dans le traitement des angiopathies diabetiques. *Lille Med Suple* **6**:XIII, 1968
4. Navder KP, Baraona E, Lieber C: Polyenyphosphatidylcholine decreases alcoholic hiperlipemia without affecting the alcohol-induced rise of HDL cholesterol. *Life Sci* **61**:1907, 1997
5. Bobkova VI, Lokchinal I, Korsunsk, Tamamova GV: Metabolic effect of lipostabilforte. *Kardiologĭa* **29**:57, 1989
6. Pogozeva AV, Bobkova SN, Samsonov MA, Vasil'ev AV: Comparative evaluation of hypolipidemic effects of omega-3 polyunsaturated acids and Lipostabil. *Vopr Pitan* **4**:31, 1996
7. Montgomery R, Conway .: *Biochemistry, a Case-Oriented Approach*. 5th ed. St. Louis, MO, C.V. Mosby, 1994
8. Nattermann Phospholipid GmbH *Phospholipids and liposomes* Scientific Publication 2, , 1995
9. Cosmetic Ingredient Review Final report on the safety assessment of lecithin and hydrogenated lecithin. *Int J Toxicol* **20**(Suppl):21-45, 2001